



PATIENT

Koda Fallihee

SPECIES

Canine

BREED

Golden Retriever

SEX

MI

AGE

4.5yr

WEIGHT

82.8lb

INTERPRETED BY

R. McKenzie Daniel,
DVM, DABVP
(Canine and Feline)

IMAGING PERFORMED BY

Karla Schultz

HOSPITAL NAME

Northshore Veterinary
Hospital

REFERRING VET

Karla Schultz

INVOICE

24508

DATE

04/14/2026

PRESENTING CLINICAL SIGNS

Screening abdominal ultrasound, a GI stromal tumor was removed (ileocolic anastomosis, 1cm histo margins) in 2023 with local lymph node removal. P has had no symptoms since that time. Chest rads also submitted (separately) due to new cardiac murmur auscultated today.

Abnormal PE/Chem/CBC/UA Results: PE: overweight, 2/6 left basilar systolic murmur with normal rhythm and no pulse deficits, normal rectal exam CBC/chem: submitted, pending chest radiographs: submitted, pending Last AUS Dec 2024: 1) Normal stomach containing mild ingesta 2) Normal visualized small bowel / colon with subjective semi-formed fecal matter in colon

ULTRASONOGRAPHIC EXAMINATION OF THE ABDOMEN

Urinary System

The urinary bladder, trigone, cystourethral junction, and visible pelvic urethra exhibited normal thickness and tone. Anechoic urine was present in the lumen with no evidence of urine/lumen sediment, mineral, or calculi. The ureteral papillae were normal. The ureters were not visible, which is normal. No evidence of inflammatory or neoplastic changes was noted.

Normal size and margination were present in the kidneys. A normal 1:3 cortex / medulla ratio and normal corticomedullary definition were maintained. The echogenicity of the cortex was similar to or slightly less than normal liver parenchyma while the medulla echogenicity was hypoechoic to the cortex with no evidence of pelvic dilation. The left kidney measured 6.6 cm in length. The right kidney measured 6.2 cm in length.

The area of the aortic trifurcation was free of pathology.

The prostate was mildly enlarged in size with intact, symmetrical capsule contour. The margins of the gland were intact and able to be differentiated from the surrounding tissue. The prostatic parenchyma was mildly echogenic to heteroechoic without parenchymal mineralization. The prostate measured 3.0 cm in diameter.

Adrenal Glands

The left adrenal gland was uniform in size and contour with a uniformly hypoechoic parenchyma. The left adrenal gland measured 0.63 cm width at the caudal pole. The right adrenal gland was uniform in size and contour with a uniformly hypoechoic parenchyma. The right adrenal gland measured 0.55 cm width at the caudal pole.

Spleen

The spleen exhibited a finely textured and homogenous parenchyma which was hyperechoic to the liver and renal cortical parenchyma. The capsule was smooth and regular without apparent expansion. The splenic vasculature at the hilus was normal in volume with no evidence of congestion or thrombosis. Acute to chronic inflammatory, neoplastic, or benign parenchyma changes were not noted.

Liver/Gallbladder

The liver was subjectively normal in size, structure, and contour. The liver parenchyma was uniform and hypoechoic to the spleen with a mild coarse echotexture. Normal vascular volume. The hepatic



PATIENT

Koda Fallihee

and portal vasculature were normal in appearance without signs of congestion. The gallbladder was non-distended in size with thin walls and primarily anechoic luminal content. The cystic and common bile ducts were normal.

SPECIES

Canine

Gastrointestinal

The stomach presented intact wall layering with a normal wall layer ratio. The lumen of the stomach was empty with no signs of ileus, obstruction or foreign material.

BREED

Golden Retriever

The small intestine presented intact wall layering with 1:3 muscularis/mucosa ratio. The lumen of the small intestine was empty with no signs of mechanical/metabolic ileus, obstruction or foreign material.

Normal visible colon wall layers were present with apparent formed feces in lumen.

SEX

MI

Pancreas

The parenchyma of the left limb, body and right limb of the pancreas presented isoechoic to the adjacent omental fat. A normal curvilinear capsule contour of the pancreas was present. The visible pancreatic duct was normal. No signs of active inflammation or neoplastic disease was evident.

AGE

4.5yr

Free Abdomen

No omental masses, overt lymphadenopathy or peritoneal effusion was present.

WEIGHT

82.8lb

ULTRASONOGRAPHIC FINDINGS

Primary

- Sonographically unremarkable abdomen
- Mild benign prostatic hyperplasia

INTERPRETED BY

R. McKenzie Daniel,
DVM, DABVP
(Canine and Feline)

INTERPRETATION OF THE FINDINGS & FURTHER RECOMMENDATIONS

No evidence of visceral pathology, specifically recurrent gastrointestinal pathology or evidence of primary / metastatic criteria. Continued as needed sonographic monitoring based on oncology recommendations is suggested.

IMAGING PERFORMED BY

Karla Schultz

HOSPITAL NAME

Northshore Veterinary
Hospital

REFERRING VET

Karla Schultz

INVOICE

24508

DATE

04/14/2026



PATIENT

Koda Fallihee

SPECIES

Canine

BREED

Golden Retriever

SEX

MI

AGE

4.5yr

WEIGHT

82.8lb

INTERPRETED BY

R. McKenzie Daniel,
DVM, DABVP
(Canine and Feline)

IMAGING PERFORMED BY

Karla Schultz

HOSPITAL NAME

Northshore Veterinary
Hospital

REFERRING VET

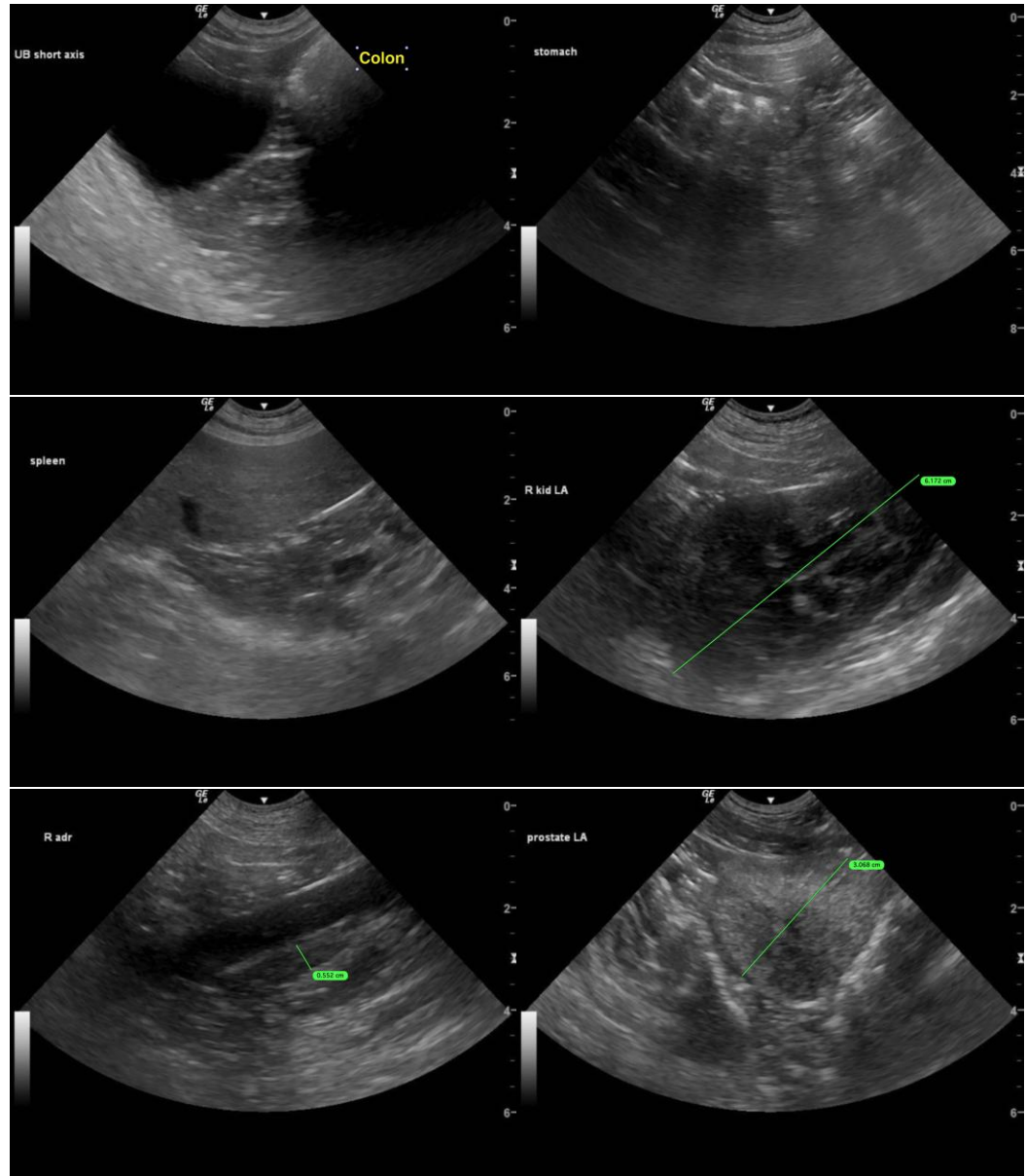
Karla Schultz

INVOICE

24508

DATE

04/14/2026





PATIENT

Koda Fallihee

SPECIES

Canine

BREED

Golden Retriever

SEX

MI

AGE

4.5yr

WEIGHT

82.8lb

INTERPRETED BY

R. McKenzie Daniel,
DVM, DABVP
(Canine and Feline)

IMAGING PERFORMED BY

Karla Schultz

HOSPITAL NAME

Northshore Veterinary
Hospital

REFERRING VET

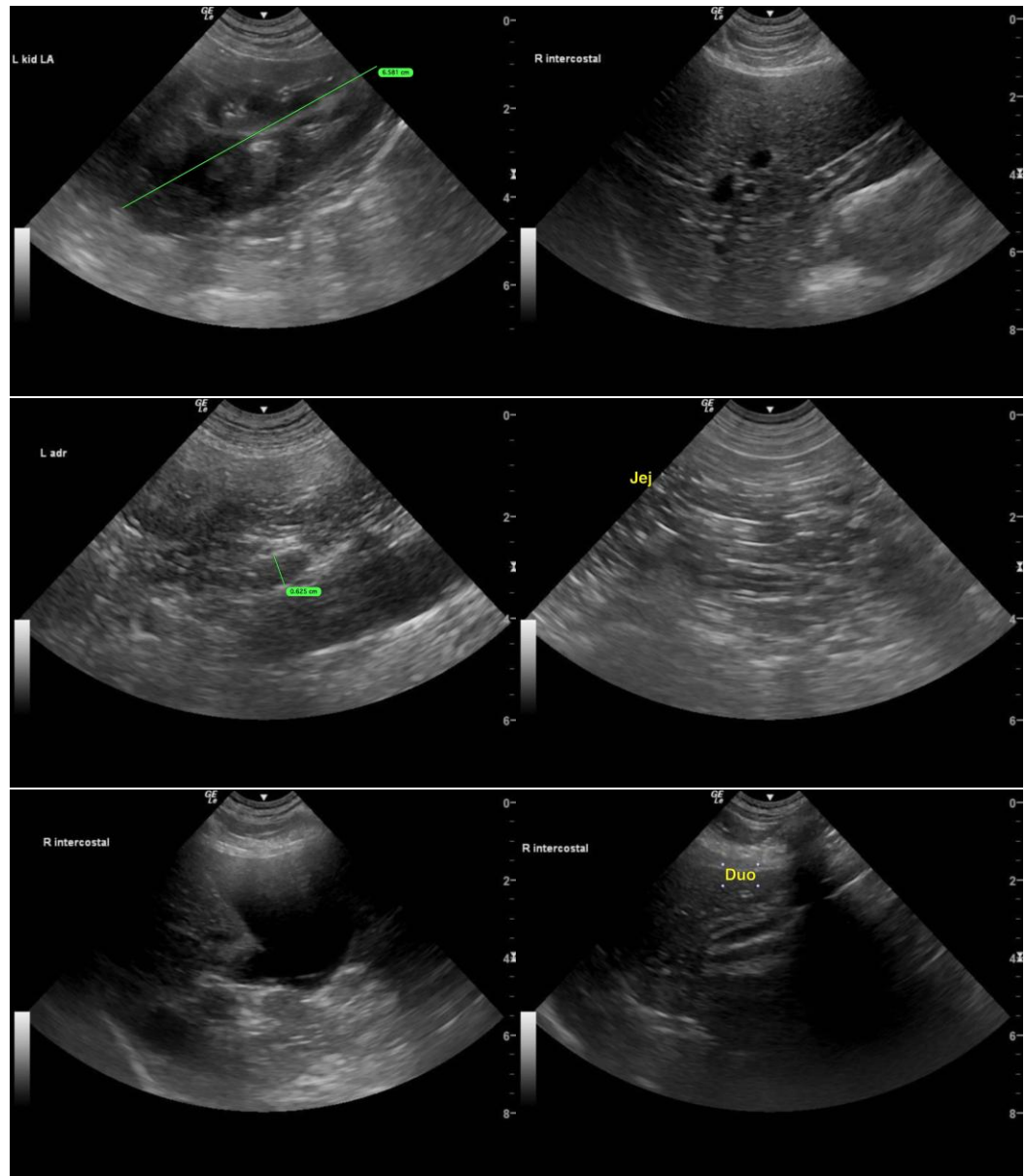
Karla Schultz

INVOICE

24508

DATE

04/14/2026



The information and recommendations provided are based on the images presented by the referring veterinarian/sonographer. No evaluation can be communicated regarding pathology that was not visible in the image/video clips provided.

Thank you for this referral. If the clinical or image interpretation does not parallel your findings or if I can be of any further assistance, please contact me.

R. McKenzie Daniel, DVM, DABVP (Canine/Feline Practice)



PATIENT

info@sonopath.com

Koda Fallihee

SPECIES

Canine

BREED

Golden Retriever

SEX

MI

AGE

4.5yr

WEIGHT

82.8lb

INTERPRETED BY

R. McKenzie Daniel,
DVM, DABVP
(Canine and Feline)

IMAGING PERFORMED BY

Karla Schultz

HOSPITAL NAME

Northshore Veterinary
Hospital

REFERRING VET

Karla Schultz

INVOICE 24508

DATE
04/14/2026